

## **INCREASED MIDSAGITTAL TONGUE VELOCITY AS INDICATION OF ARTICULATORY COMPENSATION IN PATIENTS WITH LATERAL PARTIAL GLOSSECTOMIES**

Orchid Rastadmehr, MA,<sup>1</sup> Tim Bressmann, PhD,<sup>1</sup> Ron Smyth, PhD,<sup>2,3</sup>  
Jonathan C. Irish, MD, MSc, FRCSC<sup>4</sup>

<sup>1</sup> Department of Speech-Language Pathology, University of Toronto, Toronto, Canada. E-mail: tim.bressmann@utoronto.ca

<sup>2</sup> Department of Linguistics, University of Toronto, Toronto, Canada

<sup>3</sup> Department of Psychology, University of Toronto, Toronto, Canada

<sup>4</sup> Department of Otolaryngology/Surgical Oncology, Princess Margaret Hospital, University of Toronto, Toronto, Canada

Accepted 14 September 2007

Published online 22 January 2008 in Wiley InterScience (www.interscience.wiley.com). DOI: 10.1002/hed.20772

---

**Abstract:** *Background.* The purpose of this study was to describe the impact of partial lateral glossectomy on midsagittal tongue movement during speech.

*Methods.* Using B-mode ultrasound, the midsagittal tongue movement of 10 patients with lateral partial glossectomy during a standardized reading passage was analyzed before and after surgery. Six normal adults served as control speakers. The main outcome measure was the tongue velocity during speech. The technique of defect reconstruction (local vs flap) was included as a covariate in the analysis.

*Results.* Following the surgery, all patients significantly increased the velocity of the midsagittal tongue movements during the reading passage.

*Conclusion.* The results demonstrated that the patients with partial glossectomy compensated for the lateral tongue resections by increasing the velocity of the residual tongue during

speech. The study provides first insights into the biomechanical aspects of spontaneous articulatory compensation following lateral tongue resections. ©2008 Wiley Periodicals, Inc. *Head Neck* 30: 718–726, 2008

**Keywords:** speech; head and neck cancer; glossectomy; ultrasound imaging; tongue

**A** partial tongue resection and reconstruction can significantly interfere with a patient's ability to speak and interact socially, which will have a detrimental impact on his or her quality of life.<sup>1</sup> A loss of lingual tissue will interfere with the normal movement of the tongue, result in a reduced range of movement,<sup>2,3</sup> and cause speech distortions.<sup>4</sup> A number of studies on glossectomy speech have described the performance of individual patients or small patient groups.<sup>5–8</sup> Some researchers have used instrumental phonetic methods such as spectrography,<sup>9</sup> videofluoroscopy,<sup>10</sup> or electropalatography<sup>11</sup> in single case studies. Other researchers have investigated word intelligibility,<sup>12</sup> syllable

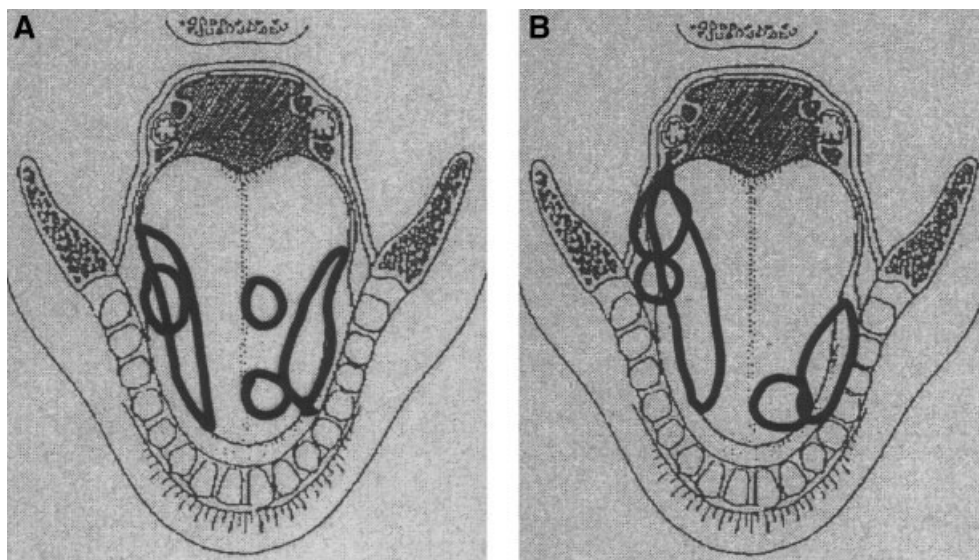
---

Correspondence to: T. Bressmann

Parts of this article were presented as a poster at the Annual Convention of the American Academy for Otolaryngology–Head and Neck Surgery in Toronto, Ontario, September 17–20, 2006.

Contract grant sponsor: Canadian Institutes of Health Research.

© 2008 Wiley Periodicals, Inc.



**FIGURE 1.** Graphical representation of the tumor sizes and locations as documented by the surgeon. (A) Patients with local defect closure. (B) Patients with flap closure.

repetition rate,<sup>13</sup> vowel formants,<sup>14</sup> electropalatographic contact patterns,<sup>15</sup> and sagittal tongue shapes.<sup>16</sup>

A number of surgical variables determine postoperative speech and tongue function. It has been suggested that the extent,<sup>17</sup> the site,<sup>18,19</sup> or the reconstruction of the defect are the crucial factors.<sup>20</sup> Pauloski et al<sup>3</sup> assessed the speech and surgical results from 142 patients and concluded that the extent of the resection correlated with the decrease in articulatory precision, and that flap reconstructions led to poorer outcomes than local closures. However, the defects that were closed with flaps were considerably larger than those closed locally. Nicoletti et al<sup>2</sup> used an automatic speech-analyzer to assess speech production in 196 patients. Using correlation analyses, the authors demonstrated that larger resections led to poorer speech results. Local reconstructions led to better results than flap reconstructions when the group was analyzed as a whole, but comparisons in location subgroups failed to differentiate between reconstructive techniques.

One constant problem in the study of glossectomy speech has been the visualization of dynamic tongue movement. It has proven difficult to assess the effect of a tumor resection on the movement of the tongue during speech because the tongue is concealed in the oral cavity. Researchers have used electropalatography to visualize linguopalatal contact patterns.<sup>11,15</sup> However, the electropalatograph only provides indirect information about tongue movement. Videofluoroscopy provides a more com-

plete picture of tongue movement<sup>10</sup> but exposes the patient to radiation. MRI has so far been limited to static visualizations.<sup>16</sup>

The goal of this study was to document the impact of a lateral tongue resection on the speed of tongue movement in patients before and after a partial lingual resection, using midsagittal B-mode ultrasound imaging. Ultrasound is a practical, biologically safe, and patient-friendly way of imaging the tongue for speech research in normal and disordered populations.<sup>21–23</sup> It was expected that the patients would show decreased lingual velocity in speech following the resection. This expectation was based on the assumption that scarring of the defect site would tether the residual tongue and restrict function.<sup>17</sup> The technique used for defect reconstruction (local closure vs flap reconstruction) was also taken into account.

## MATERIALS AND METHODS

**Participants.** Ten patients with tongue cancer (5 patients with T1, 3 with T2, and 2 with T3 tumors) took part in this study. The mean age of the group was 45 years, with a standard deviation of 8.4 years and a range of 34 to 64 years. Following the partial lateral tongue resections, 5 patients received local closure reconstruction, and 5 patients underwent microvascular free flap reconstruction (3 radial forearm flaps and 2 anterolateral thigh flaps). The extent of the resection was documented using a graphical mapping protocol.<sup>2,24</sup> The results of the graphical mapping may



urements were within 1 mm, and 93% within 2 mm of each other. No single measurement error exceeded 3 mm. Since the manufacturer of the ultrasound machine estimates the accuracy of the ultrasound image to be within  $\pm 1$  mm, these results were deemed acceptable.

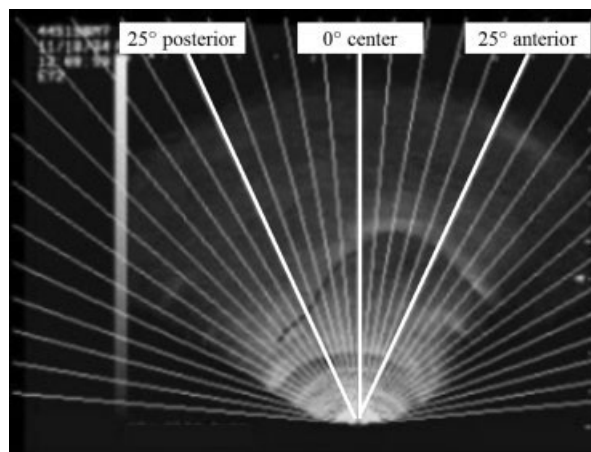
The tongues of different speakers may vary in length. As a result, an unequal number of measurement points may be obtained between speakers. As previously reported,<sup>22,23</sup> the measurement points between 25° anterior and 25° posterior can usually be reliably recorded in all participants. However, the measurement points at 30° or at wider angles may yield missing data in some patients. In order to reduce the overall volume of the data for the analysis, 3 representative measurement points were selected. The measurements at 25° posterior capture the movement of the posterior tongue, those at 0° the dorsum of the tongue, and those at 25° anterior the tongue blade (Figure 4).

The distance data were used to calculate the velocity of the midsagittal tongue at the measurement points 25° posterior, 0°, and 25° anterior. The tongue height in each ultrasound frame was subtracted from the tongue height in the next frame. Because the manufacturer of the ultrasound machine reports a measurement accuracy of  $\pm 1$  mm, height differences of less than 1 mm were discarded. In order to calculate the average velocity at each of the 3 measurement angles, the absolute values of the height differences were added up and divided by the total time of the movie sequence.

## RESULTS

**Reading Time.** The average time that it took each patient to read the first 4 sentences of the Grandfather passage was 12.99 seconds (SD = 0.5934) at the preoperative assessment and 13.16 seconds (SD = 0.5835) at the postoperative assessment. The increase in time was not statistically significant according to a paired samples *t* test:  $t(9) = 1.176$ ,  $p = .270$ . The control speakers read the same passage in 13.47 seconds (SD = 0.8548). According to the results of 2 independent samples *t* tests, there were no significant differences in the mean reading times between the normal speakers and the patients before ( $t(14) = 1.322$ ,  $p = .207$ ) or after the partial glossectomy surgery ( $t(14) = 0.857$ ,  $p = .406$ ).

**Tongue Velocity.** Table 1 shows the mean values and standard deviations for the average lingual



**FIGURE 4.** Midsagittal view of the tongue with superimposed measurement grid. The grid angles that were used for the subsequent statistical analyses are highlighted.

height in the patients before and after the operation, and in the normal participants. The average lingual height for every measurement angle was calculated by adding up all measurement values at this angle and calculating the mean. The measurement values at the different angles demonstrate that, in the patients, the distance of the midsagittal tongue surface from the transducer during speech increased postoperatively. The height measurements were used to calculate the tongue velocity, as described earlier. A summary of the results for lingual velocity can be found in Table 2 and Figure 5. The patients moved their tongues at an average speed of 0.029 m/s (SD = 0.0027) before the partial glossectomy as opposed to 0.044 m/s (SD = 0.0065) after the surgery. The average velocity in the patients after the operation was higher than in the normal speakers (mean, 0.038 m/s; SD = 0.0084).

### Comparison of the Tongue Velocity in Patients with Tongue Cancer before and after Glossectomy Surgery.

All statistical analyses were conducted for 3 representative points on the midsagittal tongue surface: 25° posterior represented the posterior tongue (“posterior”), 0° represented the center (“center”), and 25° anterior represented the anterior tongue (“blade”; see Figure 2). To compare the velocity of movement in these 3 lingual segments before and after the glossectomy operation, a mixed  $2 \times 3 \times 2$  analysis of variance (ANOVA) was used. Time (preoperation: “pre”; and postoperation: “post”) and tongue segment (posterior, center, and blade) constituted the within-subject factors. The type of the reconstructive

**Table 1.** Tongue height in patients with tongue cancer before glossectomy, in patients with tongue cancer after glossectomy, and in normal speakers.

Subject number	Condition	Reconstruction	Tongue height, mean (SD), mm		
			Posterior 25°	Center 0°	Anterior 25°
1	Preglossectomy		54.09 (3.83)	52.13 (2.84)	48.02 (3.72)
1	Postglossectomy	Local closure	58.86 (4.84)	64.99 (1.98)	67.58 (3.96)
2	Preglossectomy		50.33 (5.90)	53.90 (3.86)	56.82 (5.24)
2	Postglossectomy	Local closure	57.56 (5.69)	62.66 (4.90)	62.47 (6.22)
3	Preglossectomy		39.22 (3.21)	41.93 (2.66)	49.35 (2.90)
3	Postglossectomy	Local closure	55.49 (3.40)	56.52 (3.04)	66.71 (3.07)
4	Preglossectomy		55.79 (4.09)	54.60 (2.97)	41.56 (3.53)
4	Postglossectomy	Local closure	56.67 (2.90)	66.05 (2.15)	63.74 (3.43)
5	Preglossectomy		57.26 (3.53)	52.81 (2.80)	46.71 (3.67)
5	Postglossectomy	Local closure	53.57 (4.65)	64.61 (3.14)	64.92 (3.81)
6	Preglossectomy		50.64 (1.79)	53.05 (1.68)	50.95 (2.95)
6	Postglossectomy	Free flap	59.80 (3.36)	61.96 (5.54)	63.96 (3.70)
7	Preglossectomy		46.43 (4.94)	40.83 (3.97)	40.50 (3.78)
7	Postglossectomy	Free flap	56.28 (4.21)	58.51 (5.44)	67.06 (4.17)
8	Preglossectomy		31.48 (2.82)	42.61 (4.50)	46.69 (4.97)
8	Postglossectomy	Free flap	51.47 (5.19)	62.52 (4.60)	68.19 (5.28)
9	Preglossectomy		46.37 (3.64)	48.81 (3.95)	48.71 (3.53)
9	Postglossectomy	Free flap	63.64 (5.22)	56.41 (3.57)	56.46 (2.86)
10	Preglossectomy		41.36 (3.41)	39.81 (2.29)	38.60 (2.09)
10	Postglossectomy	Free flap	50.37 (2.84)	55.28 (3.46)	59.37 (3.30)
11	Normal speaker		49.29 (4.85)	57.98 (4.21)	58.87 (4.61)
12	Normal speaker		42.58 (7.31)	57.64 (2.56)	53.75 (3.77)
13	Normal speaker		49.97 (5.48)	61.84 (3.54)	65.50 (3.96)
14	Normal speaker		40.54 (5.57)	48.41 (3.68)	50.52 (5.57)
15	Normal speaker		38.58 (6.43)	57.96 (4.47)	64.56 (4.95)
16	Normal speaker		39.84 (4.05)	46.50 (2.14)	50.61 (3.49)

tion (local closure and free flap) was the between-subject factor. The analysis revealed a significant main effect of time:  $F(1, 8) = 228.74, p < .001$ ; and of tongue segment:  $F(2, 16) = 17.9, p < .001$ .

A significant interaction was found between the factors time and tongue segment:  $F(2, 16) = 5.27, p < .05$ . Correlated samples  $t$  tests were used to further investigate this interaction. The  $t$  tests indicated significant mean differences between preposterior and postposterior:  $t(9) = 12.63, p < .001$ ; between precenter and postcenter:  $t(9) = 5.11, p < .002$ ; and between preblade and postblade:  $t(9) = 8.72, p < .001$ , demonstrating that the velocity of all tongue segments increased significantly after the glossectomy.

No significant interactions were found between the factors time and type of reconstruction:  $F(1, 8) = 0.653, p = .442$ ; between the factors tongue segment and type of reconstruction:  $F(2, 16) = 0.545, p = .590$ ; or between the factors time, tongue segment, and type of reconstruction:  $F(2, 16) = 0.296, p = .747$ . The between-group analysis across the 2 groups of patients with different types of reconstruction (local closure and free flap) did not yield a significant main effect of patient group:  $F(1, 8) = 0.55, p = .48$ .

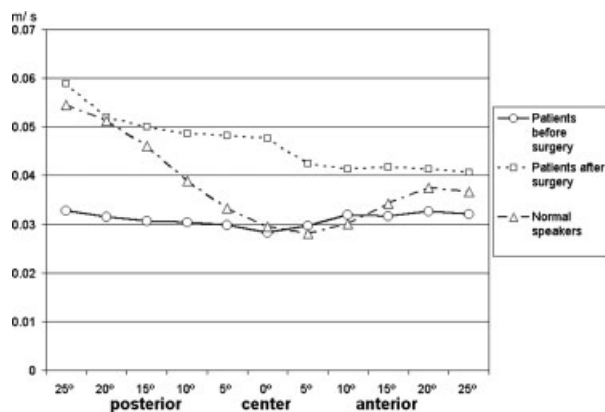
**Comparison of Tongue Velocity in Patients before and after Glossectomy Surgery, and in the Normal Speakers.** The tongue velocities of the normal speakers, the patients with local closure, and the patients with free flaps were compared for the preoperative and postoperative examinations. For each session, a  $3 \times 3$  mixed ANOVA was used. The factor tongue segment (posterior, center, and blade) was the within-subjects factor and the factor participant's condition (the patients with local closure reconstruction ["local"] the patients with free flap reconstruction ["flap"] and the normal speakers [normal]) was the between-subjects factor.

The analysis revealed a significant main effect of tongue segment for the preoperative session:  $F(2, 26) = 6.589, p < .01$ ; as well as for the postoperative session:  $F(2, 26) = 17.561, p < .001$ . The between-group analysis across the 3 conditions indicated a significant main effect of the participants' condition before:  $F(2, 13) = 6.811, p < .01$  and after the glossectomy surgery:  $F(2, 13) = 4.596, p < .04$ . There was no significant interaction between the factors tongue segment and condition before:  $F(4, 26) = 3.126, p = .073$  and after the surgery:  $F(4, 26) = 1.441, p = .249$ . Multiple Bonferroni comparisons were conducted to further

**Table 2.** The average velocity of tongue movement in patients with tongue cancer before and after glossectomy, and in normal speakers.

Subject number	Condition	Reconstruction	Velocity, mean (SD), m/s		
			Posterior 25°	Center 0°	Anterior 25°
1	Preglossectomy		0.03566 (0.06)	0.02111 (0.02)	0.03012 (0.02)
1	Postglossectomy	Local closure	0.06292 (0.05)	0.04105 (0.03)	0.04256 (0.02)
2	Preglossectomy		0.03359 (0.06)	0.02806 (0.06)	0.03228 (0.05)
2	Postglossectomy	Local closure	0.05604 (0.04)	0.05478 (0.07)	0.04792 (0.03)
3	Preglossectomy		0.02694 (0.03)	0.02025 (0.05)	0.03697 (0.01)
3	Postglossectomy	Local closure	0.06202 (0.01)	0.06554 (0.03)	0.04271 (0.06)
4	Preglossectomy		0.04147 (0.02)	0.03135 (0.02)	0.02731 (0.02)
4	Postglossectomy	Local closure	0.05235 (0.04)	0.04269 (0.07)	0.04172 (0.01)
5	Preglossectomy		0.03283 (0.03)	0.02819 (0.04)	0.03798 (0.04)
5	Postglossectomy	Local closure	0.06334 (0.02)	0.03874 (0.05)	0.03684 (0.06)
6	Preglossectomy		0.02822 (0.05)	0.02699 (0.02)	0.03589 (0.02)
6	Postglossectomy	Free flap	0.05956 (0.01)	0.04723 (0.06)	0.04042 (0.05)
7	Preglossectomy		0.03502 (0.02)	0.03573 (0.01)	0.02718 (0.05)
7	Postglossectomy	Free flap	0.06154 (0.06)	0.04565 (0.02)	0.04195 (0.01)
8	Preglossectomy		0.02329 (0.04)	0.03201 (0.04)	0.03423 (0.03)
8	Postglossectomy	Free flap	0.06417 (0.04)	0.05195 (0.03)	0.03988 (0.01)
9	Preglossectomy		0.03305 (0.04)	0.03059 (0.04)	0.03004 (0.01)
9	Postglossectomy	Free flap	0.06401 (0.01)	0.03922 (0.03)	0.03947 (0.01)
10	Preglossectomy		0.03727 (0.07)	0.02854 (0.06)	0.02853 (0.03)
10	Postglossectomy	Free flap	0.04284 (0.05)	0.04993 (0.01)	0.03274 (0.04)
11	Normal speaker		0.04529 (0.02)	0.03809 (0.05)	0.04085 (0.02)
12	Normal speaker		0.08647 (0.05)	0.02280 (0.01)	0.03131 (0.01)
13	Normal speaker		0.04105 (0.03)	0.03362 (0.03)	0.03608 (0.06)
14	Normal speaker		0.04744 (0.02)	0.02832 (0.02)	0.04203 (0.02)
15	Normal speaker		0.07204 (0.01)	0.03571 (0.05)	0.03924 (0.03)
16	Normal speaker		0.03523 (0.01)	0.01834 (0.03)	0.03096 (0.04)

investigate the significant main effects. The multiple comparisons for the preoperative session showed significant differences between the tongue velocity of the patients with local closure and that of the normal speakers ( $p < .03$ ), and between the tongue velocity of patients with free flaps and that of the normal speakers ( $p < .03$ ). Thus, the lingual



**FIGURE 5.** Line graph of the average movement velocities (in meters per second) at different points of the midsagittal tongue surface in patients with tongue cancer before and after glossectomy, and in normal speakers.

velocity of all the patients before glossectomy was significantly lower than that of the normal speakers. In order to identify which tongue segments the patients before glossectomy moved more slowly than the normal speakers, a series of additional  $t$  tests was conducted. The  $t$  tests indicated a significant mean difference between normal-center and local-center:  $t(4) = 5.205, p < .007$ ; and marginally significant mean differences between normal-posterior and local-posterior:  $t(4) = 2.689, p = .055$ , and between normal-posterior and flap-posterior:  $t(4) = 2.768, p = .051$ . No significant differences were found between any other tongue segments across the 3 groups (local, flap, normal). The patients before glossectomy moved their posterior tongue more slowly than the normal speakers.

The multiple Bonferroni comparisons for the postoperative session indicated a significant difference between the tongue velocity of the patients with local closure and that of the normal speakers ( $p < .05$ ) and a marginally significant difference between the tongue velocity of the patients with free flaps and that of the normal speakers ( $p = .052$ ). Thus, the lingual velocity of

both groups of patients was significantly higher than that of the normal speakers. In order to identify the tongue segment that the patients after glossectomy moved faster than the normal speakers, *t* tests were conducted. The *t* tests indicated a significant mean difference between normal-center and flap-center:  $t(4) = 14.734, p < .001$ , and a marginally significant difference between normal-center and postcenter:  $t(4) = 2.704, p = .054$ . No significant mean differences were found between the other tongue segments across the 3 groups (local, flap, normal). After the surgery, the glossectomees moved the center part of their tongue faster than the normal speakers.

## DISCUSSION

A partial glossectomy surgery can significantly alter a patient's tongue shape and movement. As a result, oral function and speech may be negatively affected, which in turn may have detrimental effects on the quality of life.<sup>1</sup> It is therefore of paramount importance for head and neck surgeons, speech-language pathologists, and other involved medical professions to develop a better understanding of the biomechanical effects of a lingual resection and reconstruction.

The present study used ultrasound imaging to capture tongue movement in speech. The ultrasound imaging and the subsequent quantitative data analysis provided informative results. At the same time, the imaging method was noninvasive and reasonably comfortable for the research participants. A notable feature of this research study is that a phonetically varied reading passage was used. This is in keeping with a current trend in speech science research to use more ecologically valid speech stimuli for kinematics and acoustic research.<sup>26</sup>

The main outcome measure of this research project was the velocity of the midsagittal tongue movement. The analysis was limited to 3 data points chosen to represent the tongue movement at the blade, dorsum, and posterior tongue. The results indicate that these 3 points sufficiently captured the speed of movement in the different segments of the tongue.

The comparison between the patients and the normal speakers demonstrated that the patients' tongue movement before the operation was slower than in the normal speakers. While this difference was statistically significant, it is impossible to decide whether this finding is clinically relevant based on the present study. The lower velocity in

the patients could be interpreted as a protective mechanism, aimed at minimizing pain or discomfort related to the lingual carcinoma. However, it is important to keep in mind that 2 comparatively small groups of speakers with a natural, uncontrolled variety of tongue sizes and shapes were compared in the present study. The purpose of the control group was to provide first orienting values about what could be considered "normal" in this new and largely uncharted field of research.

Previous research had postulated that a glossectomy operation would decrease lingual range and speed of movement.<sup>4</sup> Contrary to our expectations, the results indicated that patients with glossectomy in this study significantly increased the speed of their midsagittal tongue movement following a lateral resection and reconstruction. This effect was seen in all patients, whether they had undergone local closure or flap reconstruction. The velocity of tongue movement increased significantly in all anatomical regions of the tongue (blade, dorsum, and base). The analysis of the mean reading time for the passage demonstrated that the increase in velocity was not related to a faster speaking rate.

This finding may appear paradoxical at first. It is counterintuitive that a lateral ablation should lead to an increase in midsagittal movement speed. However, recent research in patients with hemiparetic stroke demonstrates that a unilateral loss in physical function leads to compensatory motor learning.<sup>27</sup> The unaffected side of the body will compensate for the affected side.<sup>28,29</sup> Doyle<sup>30</sup> describes the phenomenon of hypertonic compensation after partial laryngectomies, which can lead to hyperfunctional voice disorders. A recent imaging study in a group of patients with glossectomy indicated increased activity in the parietal lobes and the cerebellum that was indicative of active compensatory adaptation to the structural defects.<sup>31</sup> In the present study, such compensatory processes may explain the increased speed of tongue movement. In an attempt to compensate, the patients were articulating with more effort, which resulted in higher velocity of movement.

It should be noted that the present study was limited by a number of factors. The patient group was relatively small, and the convenience sampling approach did not necessarily produce a representative sample of tumor locations and sizes. The patients in our study were evaluated relatively early after the partial tongue resection and reconstruction. None of the patients had undergone radiation treatment, which may cause muscle fibrosis

as a side effect. As a next step, it will be necessary to investigate whether the increase in velocity will persist or whether the velocity will return to preoperative levels over the longer term. It will also be necessary to investigate the relationship between lingual velocity and speech outcome measures such as intelligibility and acceptability.

Despite the limitations of the present study, the results raise interesting additional questions about the postoperative management of glossectomy speakers. The literature in speech-language pathology about glossectomy speech rehabilitation is remarkably scant and unspecific. A common recommendation in the literature is to use nonspeech range of motion exercises, such as sticking the tongue out, moving it from side to side, etc, to increase the strength and movement of the glossectomee's tongue.<sup>32,33</sup> These exercises are applied with the implicit expectation that they will be beneficial for speech.<sup>34</sup> However, the research presented here demonstrates that these exercises may be applied to a system that is already overcompensating and possibly hyperfunctional or hypermetric. The beneficial effect of nonspeech range of motion exercises may consist of an increase in awareness of the oral structures rather than a strengthening effect or improved phonetic accuracy. Further research will have to determine the most effective treatment strategies for speech rehabilitation in patients with glossectomy.

## CONCLUSION

B-mode ultrasound imaging is a practical and patient-friendly method of investigating midsagittal tongue movement in patients with tongue cancer before and after partial glossectomy surgery. The study demonstrated that a partial lateral resection and reconstruction leads to a significant increase in midsagittal movement velocity. This finding is interpreted as evidence of increased articulatory effort, resulting from compensatory motor learning.

**Acknowledgments.** We thank Dr. Pascal Van Lieshout, Department of Speech-Language Pathology, University of Toronto, and 2 anonymous *Head & Neck* reviewers for helpful comments and feedback. We gratefully acknowledge the help of Parveen Thind, Chiang-Le Heng, and Elizabeth Ackloo with the data collection. We also thank Drs. Ralph Gilbert, Patrick Gullane, and Dale Brown at the Princess Margaret Hospital, University of Toronto, for their help with the patient recruitment.

## REFERENCES

1. Radford K, Woods H, Lowe D, et al. A UK multi-centre pilot study of speech and swallowing outcomes following head and neck cancer. *Clin Otolaryngol* 2004;29:376–381.
2. Nicoletti G, Soutar DS, Jackson MS, et al. Objective assessment of speech after surgical treatment for oral cancer: experience from 196 selected cases. *Plast Reconstr Surg* 2004;113:114–125.
3. Pauloski BR, Logemann JA, Colangelo LA, et al. Surgical variables affecting speech in treated patients with oral and oropharyngeal cancer. *Laryngoscope* 1998;108:908–916.
4. Korpijaakko-Huuhka AM, Söderholm AL, Lehtihalmes M. Long-lasting speech and oral motor deficiencies following oral cancer surgery: a retrospective study. *Log Phon Vocol* 1999;24:97–106.
5. Massengill R, Maxwell S, Pickrell K. An analysis of articulation following partial and total glossectomy. *J Speech Hear Disord* 1970;35:170–173.
6. Dworkin JP. Glossectomy: a case report. *Arch Phys Med Rehabil* 1984;63:182–183.
7. Morrish L. Compensatory vowel articulation of the glossectomee: acoustic and videofluoroscopic evidence. *Br J Disord Commun* 1984;19:125–134.
8. Bressmann T, Sader R, Whitehill TL, et al. Consonant intelligibility and tongue motility in patients with partial glossectomy. *J Oral Maxillofac Surg* 2004;62:298–303.
9. Perrier P, Savariaux C, Lebeau J, et al. Speech production after tongue surgery and tongue reconstruction. Proceedings of the IVXth International Congress of Phonetic Sciences, San Francisco, 1999. pp 1805–1808.
10. Georgian DA, Logemann JA, Fisher HB. Compensatory articulation patterns of a surgically treated oral cancer patient. *J Speech Hear Disord* 1982;47:154–159.
11. Fletcher SG. Speech production following partial glossectomy. *J Speech Hear Disord* 1988;53:232–238.
12. Bradley PJ, Hoover L, Stell PM. Assessment of articulation after surgery of the tongue. *Folia Phoniater* 1980;32:334–341.
13. Heller KS, Levy J, Sciubba JJ. Speech patterns following partial glossectomy for small tumors of the tongue. *Head Neck* 1991;13:340–343.
14. Knuuttila H, Pukander J, Maatta T, et al. Speech articulation after subtotal glossectomy and reconstruction with a myocutaneous flap. *Acta Otolaryngol* 1999;119: 621–626.
15. Imai S, Michi K. Articulatory function after resection of the tongue and floor of the mouth: palatometric and perceptual evaluation. *J Speech Hear Res* 1992;35:68–78.
16. Kimata Y, Sakuraba M, Hishinuma S, et al. Analysis of the relations between the shape of the reconstructed tongue and postoperative functions after subtotal or total glossectomy. *Laryngoscope* 2003;113:905–909.
17. Rentschler GJ, Mann MB. The effects of glossectomy on intelligibility of speech and oral perceptual discrimination. *J Oral Maxillofac Surg* 1980;38:348–354.
18. Logemann JA, Pauloski BR, Rademaker AW, et al. Speech and swallow function after tonsil/base of tongue resection with primary closure. *J Speech Hear Res* 1993;36:918–926.
19. Michiwaki Y, Schmelzeisen R, Hacki T, et al. Functional effects of a free jejunum flap used for reconstruction in the oropharyngeal region. *J Craniomaxillofac Surg* 1993; 21:153–156.
20. Konstantinovic VS, Dimic ND. Articulatory function and tongue mobility after surgery followed by radiotherapy for tongue and floor of the mouth cancer patients. *Br J Plast Surg* 1998;51:589–593.
21. Bressmann T, Heng CL, Irish JC. The application of 2D and 3D ultrasound imaging in speech-language pathology. *J Speech-Lang Path Audiol* 2005;29:158–168.

22. Bressmann T, Thind P, Bollig CM, et al. Quantitative three-dimensional ultrasound analysis of tongue protrusion, grooving and symmetry: data from twelve normal speakers and a partial glossectomee. *Clin Linguist Phon* 2005;19:573–588.
23. Bressmann T, Ackloo E, Heng CL, et al. Quantitative three-dimensional ultrasound imaging of partially resected tongues. *Otolaryngol Head Neck Surg* 2007;136:799–805.
24. Mackenzie-Beck J, Wrench A, Jackson M, et al. Surgical mapping and phonetic analysis in intra-oral cancer. In: Ziegler W, Deger K, editors. *Clinical phonetics and linguistics*. London: Whurr; 1998. pp 481–492.
25. Van Riper C. *Speech correction: principles and methods*, 4th ed. Englewood Cliffs: Prentice-Hall; 1963.
26. Weismer G. Philosophy of research in motor speech disorders. *Clin Linguist Phon* 2006;20:315–349.
27. Krakauer JW. Motor learning: its relevance to stroke recovery and neurorehabilitation. *Curr Opin Neurol* 2006;19:84–90.
28. Higginson JS, Zajac FE, Neptune RR, et al. Muscle contributions to support during gait in an individual with post-stroke hemiparesis. *J Biomech* 2006;39:1769–1777.
29. Roby-Brami A, Feydy A, Combeaud M, et al. Motor compensation and recovery for reaching in stroke patients. *Acta Neurolog Scand* 2003;107:369–381.
30. Doyle PC. *Foundations of voice and speech rehabilitation following laryngeal cancer*, 1st ed. San Diego, CA: Singular Publishing; 1994.
31. Mosier K, Liu WC, Behin B, et al. Cortical adaptation following partial glossectomy with primary closure: implications for reconstruction of the oral tongue. *Ann Otol Rhinol Laryngol* 2005;114:681–687.
32. Appleton J, Marchin J. *Working with oral cancer*. Bicester: Winslow; 1995.
33. Leonard RJ. Characteristics of speech in speakers with glossectomy and other oral/oropharyngeal ablation. In: Bernthal JE, Bankson NW, editors. *Child phonology: characteristics, assessment, and intervention with special populations*. New York: Thieme Medical Publishers; 1994. pp 54–78.
34. Logemann JA, Pauloski BR, Rademaker AW, et al. Speech and swallowing rehabilitation for head and neck cancer patients. *Oncology* 1999;11:651–659.

---

## COMMENTARY

---

### Andrew D. Palmer, MS, CCC-SLP

Department of Otolaryngology–Head and Neck Surgery, Oregon Health and Science University, Portland, Oregon 97239-3098. E-mail: palmeran@ohsu.edu

The authors have used a novel method to investigate a commonly observed clinical phenomenon, namely, the recovery of quite functional speech by most individuals after hemiglossectomy. Previous studies have documented that intelligibility and precision correlate with the extent of resection.<sup>1</sup> To date, however, an explanation of how patients regain functional speech has been incomplete. Rehabilitation is frequently aimed at strengthening or improving the range of motion of the remaining tongue musculature, but the best

methodology for doing so has never been thoroughly examined. Using ultrasound of the tongue during reading tasks, the authors convincingly demonstrate that tongue function after hemiglossectomy not only approximates the speed of motion of normal speakers but actually exceeds it.

This finding, which is quite surprising in itself, raises questions about the nature of the process that patients undergo after surgery. The subjects in the study were measured at a period of only 2 months postoperatively, and therefore, one can only speculate as to whether we are seeing the product of motor-relearning and rehabilitation or the effects of functional reserve for motor speech tasks.

In the literature, there are similar types of observations with other populations. For example, Fred McConnel et al<sup>2</sup> found that individuals after

---

*Correspondence to:* A. D. Palmer

*Head & Neck* 30: 726–727, 2008  
 Published online 22 January 2008 in Wiley  
 InterScience (www.interscience.wiley.com).  
 DOI: 10.1002/hed.20818

© 2008 Wiley Periodicals, Inc.

laryngectomy generated higher base of tongue pressures during swallowing to compensate for changes in the postoperative physiology. His finding explained why so few laryngectomees experience dysphagia and also highlighted the fact that any weakness of the base of tongue would be so detrimental to function in this group. Likewise, we may speculate as to the mechanism of recovery in the hemiglossectomy population. It is possible that the subjects in the present study have sufficient functional reserve in the remaining tongue to enable them to generate speeds that are higher than normal. Alternatively, we may be seeing the same phenomenon as a result of a motor-learning/rehabilitative process. We can also surmise that

individuals who are not able to generate these higher speeds will have the poorest speech outcomes. These findings raise interesting questions about the process of rehabilitation and the best means of achieving it and will, no doubt, be a stimulus to further investigations.

---

#### REFERENCES

1. Pauloski BR, Logemann JA, Colangelo LA, et al. Surgical variables affecting speech in treated patients with oral and oropharyngeal cancer. *Laryngoscope* 1998;108:908–916.
2. McConnel FMS, Mendelsohn MS, Logemann J. Examination of swallowing after total laryngectomy using manofluorography. *Head Neck Surg* 1986;9:3–12.